

Research Article

Current Opinion in Gynecology and Obstetrics Office Procedures in Cosmetic Gynaecology

Anagnostou N¹, Gkrozou F^{2*}, Ioannidi L³, Papadimitriou A⁴ and Tsonis O^{5,6*}

¹Department of Radiology, University Hospital of Ioannina, Greece

²Department of Obstetrics and Gynaecology, University Hospitals of Birmingham, UK

³Department of Plastic Surgery, Chelsea and Westminster NHS Foundation Trust, UK

⁴Department of Dermatology, Evangelismos Hospital, Athens Greece

⁵Department of Obstetrics and Gynaecology, University Hospital of Ioannina, Greece

⁶Centre for Reproductive Medicine, St. Bartholomew's Hospital, Barts Health NHS, UK

***Correspondence:** Orestis Tsonis, Clinical Fellow in Reproductive Medicine, Centre for Reproductive Medicine, St. Bartholomew's Hospital, Barts Health NHS, UK, Tel: +44(0)751484784; E-mail: Orestis.tsonis@gmail.com, Orestis.tsonis@nhs.net

Received date: June 27, 2021; Accepted date: Aug 31, 2021; Published date: Sept 05, 2021

Abstract

Female genital cosmetic surgery is a set of multiple procedures focused on improving genital appearance, structure, and function. Sexual dysfunction affects a large proportion of the female population and appears to be associated with distorted genital anatomy although what women perceive as normal varies vastly depending on cultural and social beliefs. Cosmetic gynaecology office procedures are simple, quick, and effective solutions to improve sexual function as well as body image with minimal interventions and minimal side-effects. In this narrative review, we present these widely used minimally invasive aesthetic gynaecology interventions, focusing on their efficacy, and reported complications. Recommendations regarding health professionals' approach and ethical issues arising are also discussed.

Keywords: Cosmetic gynaecology, vaginal prolapse, g-shot, non-invasive surgery, sexual dysfunction

Introduction

Female Genital Cosmetic Surgery (FGCS), often referred to as cosmetic gynaecology, is a set of procedures focusing on the improvement of genital appearance, structure, and function [1-3]. Most of these procedures are performed for aesthetic purposes and in some cases for functional reasons having no specific medical indication [1,2]. Labiaplasty is the most popular among these treatments [4]. Moreover, one controversial term is vaginal rejuvenation, which comprises interventions aiming at reducing the vaginal length and caliber for both aesthetic and sexually functional reasons [1,2,5]. Cosmetic gynaecology procedures are performed by several healthcare specialists including gynaecologists, urologists, and plastic surgeons and while many of these interventions are advertised for cosmetic

reasons, they may be further used for the treatment of vulvovaginal pathologies, such as significant effects of excess androgen exposure, congenital anomalies, urinary or fecal incontinence, and pelvic organ prolapse[3,6] (Figure 1).

According to World Health Organization (WHO), "sexual dysfunction covers the various ways in which an individual is unable to participate in a sexual relationship as he or she would wish" [7]. Sexual dysfunction negatively affects the Quality of Life (QoL) and increases in an age-related manner [8]. Biological (such as neurogenic, anatomical, hormonal, vascular) and psychosocial factors (such as disturbed body image perception, depression, anxiety, and some other medical conditions that may decrease sexual confidence)

play a decisive role [8]. Approximately 41% of females of reproductive age present with sexual dysfunction [9,10,11]. Although the diversity in genital anatomy is wide, recently the population of women seeking FGCS procedures, notably vaginal rejuvenation, has increased tremendously [1,2]. An increase of 30% in the rate of vaginal rejuvenation was reported by the American Society of Plastic Surgeons [12]. Increased numbers of women who are concerned about genital appearance seek information on the Internet. Several demographic parameters such as age, sexual activity, level of education, and relationship status affect genital image [13,14]. Other reasons that lead women to seek genital rejuvenation is to increase sexual satisfaction and self-confidence, but also address functional problems (such as pain during intercourse, orgasmic problems, vulvar irritation, discomfort with underwear or clothing) by altering genital anatomy [15,16]. Social and cultural factors may affect the notion of beauty among countries [17].

The aim of this review is to provide information on minimally invasive aesthetic gynaecologic procedures, and present and discuss the controversial views in the literature, as to whether they represent simple and effective methods for improvement of sexual function, or interventions with questionable efficacy and harmful effects [2].

Material and Methods

Three major search engines were included MEDLINE, PubMed and EMBASE. Relevant studies published up to April 2021 were identified focusing on cosmetic gynaecology and minimally invasive interventions for the improvement of sexual dysfunction, using the following search terms alone or in combination: cosmetic gynecology; female genital cosmetic surgery; aesthetic gynaecology; vaginal rejuvenation; vulvovaginal rejuvenation; platelet-rich plasma; energy-based devices; G-spot amplification; lipofilling; Gore-Mycromesh; silicone threads; sexual dysfunction. Only articles in English were selected apart from one in French. Information about sexual dysfunction was included for a better understanding of the effect of these treatments and its correlation with office aesthetic gynecology procedures. Criteria of exclusion were scientific papers focusing only on interventions that require general anesthesia or demand the need of operation theatre and/or close follow-up and hospital admission.

Energy-based treatments

Such methods are popular for vaginal rejuvenation due to their minimal intervention and short duration (around 8-30 minutes) [5]. Energy-based treatments seem to benefit mild-to-moderate symptoms, such as dyspareunia, and no major complications were reported [5,18]. FDA advisory

argues that further scientific evidence is needed to verify their exact effect since the simplicity of the process does not necessarily assure safety [19]. This method is also accepted in cases of Genitourinary Syndrome of Menopause (GSM) which affects the QoL and especially sexual function when a local estrogen doesn't look to improve the symptoms. Currently, the use of office techniques as an alternative treatment is investigated [19]. Many traditional hospital-based surgeries have been successful in treating vaginal relaxation and sexual dysfunction but require much longer recovery time (6-8 weeks) and are associated with complications such as bleeding and infection, compared to energy-based treatments that present only minimal adverse effects [20] (Table 1). Energy-based treatments are divided in two major devices: Lasers and Radiofrequency (RF) [19].

Lasers

Laser technology is widely used in plastic surgery, dermatology, and currently in gynaecology for vaginal rejuvenation [15]. Minimally ablative fractional laser therapy gained popularity due to its accuracy, safety, and effectiveness for skin remodeling and regeneration. Laser-based vaginal rejuvenation is a minimally invasive method for improving sexual dysfunction in cases of vaginal laxity [1,3,18]. In general, a focused light beam is produced at a specific wavelength, selected to affect a chosen molecule [3]. Nowadays there are two main types available 1) CO₂ based laser and 2) Er: YAG (erbium-doped yttrium aluminium garnet laser, erbium YAG laser). Lasers lead to enhancement of postmenopausal epithelium, vascular and collagen growth, especially type 1 collagen, and increase vaginal tightness [3,5,21]. Further studies need to be conducted to determine the optimal number of sessions and the ideal time intervals between them [18].

Laser CO₂ (10,600 nm): This intervention refers to a microablative laser that uses mid-infrared invisible light spectrum and water as its chromophore producing heat, to stimulate neocollagenesis, neovascularisation, elastin/collagen contraction, suggesting that vaginal lubrication, elasticity, and hydration of mucosal tissue are restored [1,5,15,22]. Anterior vaginal wall structure seems to be improved; hence SUI symptoms may be alleviated [23]. Clinical outcomes are very promising with regards to rejuvenation and vulvovaginal atrophy, a common condition among menopausal women, which often leads to dyspareunia [24]. Also, fractional CO₂ laser may restore vaginal rugae, which promote friction during coitus and improve sexual satisfaction [16]. Vaginal pH was restored by the release of glycogen and acidic mucins from the epithelial cells, relieving dryness, itching, dysuria, and recurrent infections [20,24].

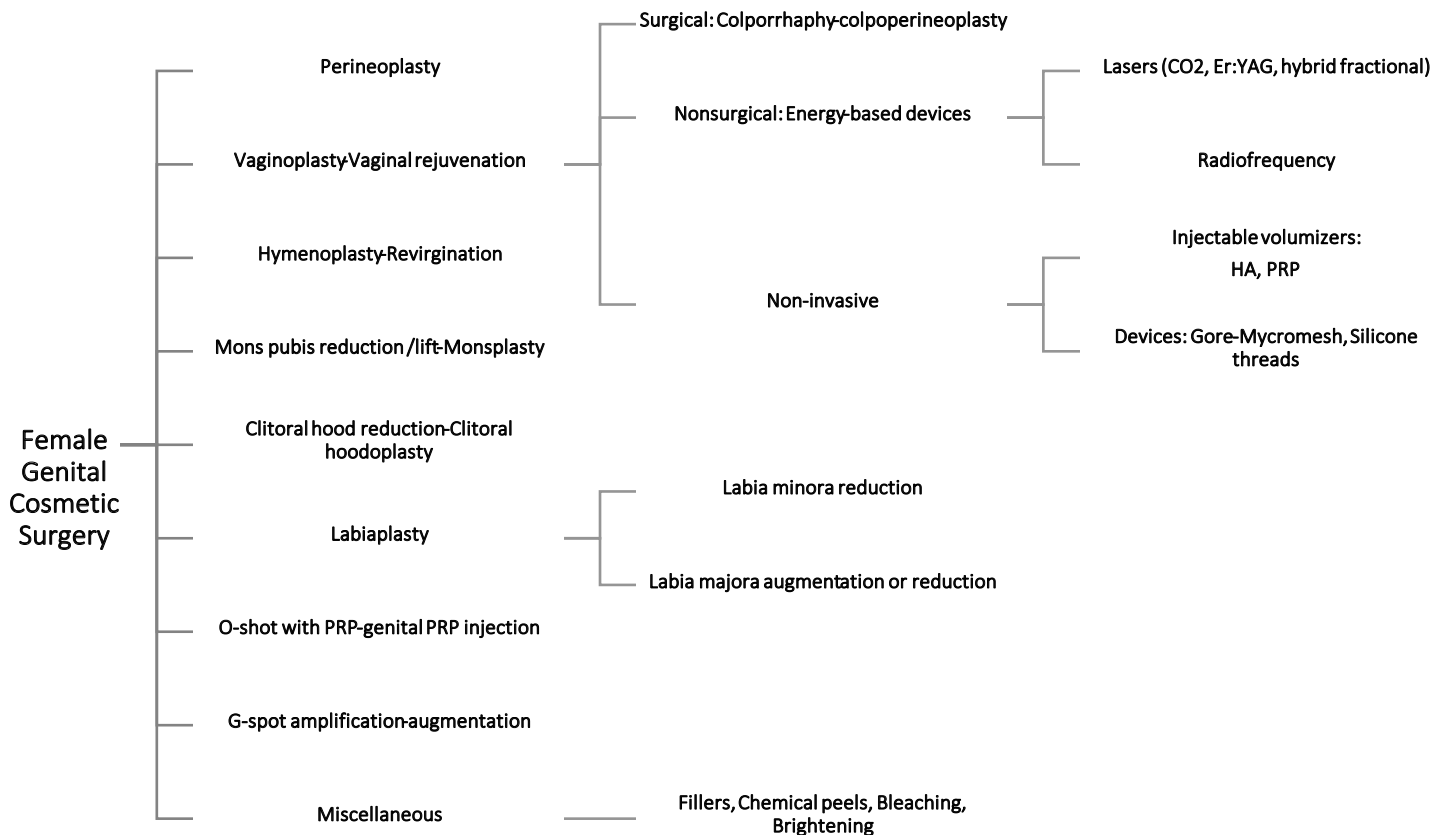


Figure 1: Outline of female genital cosmetic surgery procedures (PRP, Platelet-rich plasma; HA, hyaluronic acid).

The duration of such sessions is often between 10-20 minutes [1]. In total 3-4 sessions are recommended 4-6 weeks apart [21]. The effects of this treatment last approximately a year and therefore more sessions are required to achieve long-term maintenance [22]. Local warming/burning sensation during the procedure is reported by some patients but no anaesthesia is required. Patients often return directly to their daily activities [1,20], although, concerns arise by some clinicians regarding the unknown effects of laser treatment on adjacent organs, tissue remodeling, and damages that may lead to further dyspareunia [1].

Erbium: YAG Laser (Er: YAG) (2940 nm): This is a microablative/nonablative laser using water as chromophore for the creation of heat to a depth of 100 microns in the vaginal mucosa [15,16,21,25]. The affinity of water absorption is 10-15 times higher than that of fractional CO₂ laser [17]. The Er: YAG is a safe and efficient method with thermal only effects that leads to vaginal collagen and elastin production, remodeling, tissue contraction, and hyperthermia, which significantly improves elasticity and vaginal tightness [1,22]. The penetration depth ranges between 1-3 μm and consequently thermal damage is minimal to the surrounding tissues limiting oedema and

discomfort [17,25,26]. Additionally, this modality has a non-ablative mode (Smooth) for deep collagen remodeling stimulation and further enhancement of elasticity and tightness of the treated area [27]. The duration of the sessions is usually around 15-20 minutes [21]. A series of 2-3 sessions every 4-6 weeks is typically recommended for optimal results [21,23]. The results were very promising with minimal side-effects and seem to be more effective than local estrogen treatments [22] (Table 1). An innovative alternative method of Er: YAG laser, known as Hybrid fractional laser, offers an additional non-ablative pulse of 1470nm on the top of the 2940nm of the traditional Er: YAG laser. This second pulse amplifies tissue contraction, resulting in an additional stimulation of heat shock proteins inducing collagenesis and remodeling as a post-inflammatory response [21].

Radiofrequency treatment (RF)

RF devices have been widely used for cosmetic interventions in various areas focusing on combating cellulite, relaxation, and non-invasive fat removal. The energy produced is not absorbed by melanin, thus safety for all skin types is achieved [15,17]. Types of RF devices are monopolar, unipolar, bipolar, multipolar [27]. These devices have been proposed for symptomatic treatment of GSM, SUI, and vaginal atrophy [28]. Focused electromagnetic

Table 1: Cosmetic gynecology office procedures summary of complications.

Office procedures	Reported Complications
Energy based treatments	
Laser CO2	Mild discomfort during session, mild tissue oedema for a few days, transient increase in vaginal discharge dysuria, yeast infection, urinary tract infection, pelvic pain, recurrence of genital herpes, itching, bruising, burning sensation, numbness, mild irritation, purpura, minor bleeding [20,22]
Erbium:YAG Laser	Warmth sensation (4%), mild to moderate pain, transient edema, discomfort during the procedure, transient increase in vaginal discharge, itching, mild mucosal burns [16,20,22]
Radiofrequency	Lower abdominal pain, mild discomfort during probe insertion less than laser treatment, vaginal leukorrhea, well tolerated warmth sensation [15,20,23]
Labia majora augmentation	
Lipofilling	2.65% risk of complications, palpable fatty cysts, appearance of "camel toe", visible through clothing, exaggerated vulvar outline, swelling [3,16,32]
Hyaluronic acid injection	Transient hyperemia, edema, ecchymosis, palpable nodules.[32]
Gore-Mycromesh	False positioning, uncertain adherence, restrictions regarding longevity and tightening effects.[33]
G-spot amplification or G-shot	G-spot erosion, allergic reaction, fistula formation, infection, hematoma, bleeding, urinary complications non-thrombotic pulmonary embolism by intravascular placement. [3,16]
Platelet-rich plasma	
O-shot or Orgasm shot	Swelling may occur at the injection site lasting up to 3 days.[37]
Vaginal rejuvenation	Haematomata, non-thrombotic pulmonary embolism.[31]
Silicone threads for vaginal rejuvenation	Implant exposure, capsule contracture, infection [5,43]

waves are emitted by many currently available RF devices and generate heat to the connective tissue of the vaginal wall [1,23].

RF promotes elastin and collagen formation at tissue temperatures between 40-45° C. At the same time increases mechanical resistance of the skin by activating fibroblasts [3,5,19,27,29]. It also increases growth factor infiltration, vascularization, and local blood flow, which enhances elasticity and moisture levels of the vaginal mucosa improving sexual performance and satisfaction [17,23]. RF is very helpful in cases of vaginal laxity as it induces neoelastogenesis, as a relatively unique feature of RF [5,17]. Recently, density of small nerve fibers in the papillary dermis was proven to be promoted [5,23].

The duration of sessions is between 15-30 minutes and no anaesthesia is applied [1,15]. Burns and blisters are avoided by using software that control temperature [22]. No adverse effects were reported and mild to moderate complications, such as infection, occur less frequently [28]. Patients may resume their daily activities immediately [15].

Cur Op Gyn Obs, 4(1): 446-454 (2021)

Labia majora augmentation

Aging affects genital appearance by reducing collagen, hyaluronic acid, and fat deposition leading to wrinkles development and volume loss, which may expose labia minora [30,31,32]. These changes result in dryness and discomfort [32]. Dermal-fat grafts, autologous fat transfer (also referred to as fat grafting, fat injections, lipofilling), pedicled grafts, or injectables (hyaluronic acid) may be used with or without platelet-rich plasma (PRP) [6,9]. This treatment is indicated for restoration of labia majora anatomy, atrophy discoloration, and rhytids and benefits patient's overall sexual satisfaction [3,30].

Lipofilling

This is the most commonly used intervention for labia majora augmentation. The method includes liposuction with the use of 3mm cannula, collection of fat into 5mls syringes by patient's thigh, hips, or abdomen, and injection

of fat into the labia majora with 1,5mm injection cannula after being processed [3,10]. The volume of fat injected varies between 18-120 mls per session [30]. Multiple layers should be injected to increase fat survival [30]. Minor oedema, redness, bruising and pain at the donor site may be observed [31]. Lipofilling is a minimally invasive and efficient method for tissue volume restoration, rejuvenation, and contouring [32]. Adipose tissue is rich in adipocytes and stem cells, such as adipose tissue-derived stem cells (ADSCs) that promote tissue regeneration [31,32]. Biocompatibility and availability in large amounts are two important characteristics of autologous fat [30]. This method is simple with lower scar formation and offers a natural genital appearance [10,30]. More than one procedure may be required to reach the desired results, as slow or even partial volume loss occurs due to fat tissue inevitable absorption [10,30].

Hyaluronic acid injection

Hyaluronic acid as an injectable has many advantages with a reduced chance of allergic reaction as well as, easy inversion of ischaemic complications with hyaluronidase [30]. Also, the desired results are reached faster (2-4 months after) with hyaluronic acid than lipofilling (4-6 months after) [30]. The procedure should be performed carefully at the submucosal level exclusively to avoid side effects [30].

G-spot amplification or G-shot

In 1950, Gräfenberg described an area known as the G-spot located on the anterior vaginal wall midway between the cervix and pubic bone, 1-2 cm from the urethra, which is responsible for stimulation of systematic orgasm that differs from clitoral orgasm [16,33,34]. However scientific community defies its existence [16,35]. G-spot amplification is minimally invasive and includes hyaluronic acid, PRP, collagen, silicone, or autologous fat injection into the bladder-vaginal septum to increase G-spot's projection into the vagina (3-5mm) [3,4,34]. Digital palpation is needed prior to the procedure in order to identify the correct area of application [4].

G-spot augmentation is performed under local anesthesia and temporarily increases the size and sensitivity of the so-called G-spot for reinforcement of sensory input and stimulation with friction of the anterior vaginal wall during intercourse [3,5,34,35]. Therefore, higher frequency and intensity of vaginal orgasm are more likely to occur [4,5]. Results are not permanent with a duration varying between 5 to 9 months [4,5]. Unfortunately, there is lack of scientific evidence that supports the improvement of sexual dysfunction and safety of this procedure [34].

It needs to be mentioned that there is a risk of urethral injury, haematuria, dyspareunia, nerve damage [36,37]. It has been also mentioned a case of death from injection in the anterior vaginal wall [36,37].

Platelet-rich plasma in female sexual dysfunction (PRP)

Platelet-rich plasma (PRP) can be used as an injectable. PRP preparation is an outpatient process and can be performed in multiple ways [37]. Generally, PRP is obtained after blood collection (venous blood 15-50 mls) in anticoagulant-containing tubes and centrifugation for the removal of red blood cells [37]. It contains high levels of growth factors (such as PDGF, TGF- β , VEGF, IGF-1, FGF, HGF), chemokines, cytokines and has anti-inflammatory properties, useful in conditions such as lichen sclerosus or other autoimmune diseases [5,16,38]. Growth factors may also reinforce cell migration, differentiation, proliferation, tissue regeneration and their concentration in PRP is 5-10 times higher than that of whole blood [37,39]. Stem cells can be stimulated to produce healthy vaginal tissue [16].

Although the mechanism of action of PRP has not yet been elucidated, it seems that potentially could promote and accelerate the healing process [37]. As it is autologous, it is also nonantigenic and no adverse effects have been reported [17]. PRP injections can be proposed as alternative non-surgical method in cases of sexual dysfunction, atrophic diseases, SUI and reduced lubrication [17,40]. Unfortunately, PRP is not licensed to be used for the above indication, since the available evidence is not enough to support that. They can be used empirically though by practitioners and after the appropriate consultation of patients.

O-shot or Orgasm shot

Non-hormonal approach that Charles Runels performed for the first time for improving sexual dysfunction [40]. Local anaesthetic cream is applied onto specific vaginal areas and PRP injection is performed into the clitoris and upper vaginal wall [16,37,40]. O-shot could potentially be a useful technique for significantly improving sexual dysfunction, orgasm, and lubrication [38]. The sample of this study was very small and further studies will be needed to evaluate this technique.

Vaginal rejuvenation

Vaginal atrophy affects many peri- and post-menopausal women [32]. Rejuvenation using PRP and lipofilling seemed to relieve vaginal atrophy and provide satisfactory aesthetic improvements with regards to sexuality and QoL [32,37].

Vascularity is enhanced and, therefore sensitivity increases and sexual function too. The vaginal skin becomes firmer and thicker [37]. PRP is possible to prolong fat graft survival by enhancing blood supply and stem cell proliferation [31,32].

Vulvovaginal rejuvenation by lipofilling and injection of hyaluronic acid and combined PRP is a safe and easy method [1,5]. Hyaluronic acid enhances medical results, promotes tissue lubrication, and converts the PRP solution into a viscous solution [41].

Gore-Mycromesh

Gore-Mycromesh is a biocompatible compound with a composition of expanded polytetrafluoroethylene (ePTFE) and size 2x4 cm² [1]. Its use is popular in plastic and reconstructive surgery [41]. The procedure is performed under local anaesthesia and includes insertion of the material under the posterior vaginal wall [1,5,42]. Gore-Mycromesh can be combined with other procedures [42]. Vaginal diameter is reduced, and posterior wall reinforcement is the main advantage of this intervention [42]. Clinical outcomes revealed substantial enhancement of sexual functioning even a year after the initial intervention [1,5,42]. Graft based augmentation of the posterior vaginal wall is rarely used for cosmetic indications though, because of the increased risk of complications. So, the use of Gore-Mycromesh is not used very often even the results of sexual functioning have been encouraging [1,5,42].

Silicone threads

This procedure is performed under sedation [42]. Silicone threads are inserted under the vaginal submucosa by making incisions at 3 and 9 o'clock positions. During the operation, emphasis should be given in avoiding injuries of the rectum and urethra [42]. The method offers promising beneficial results on sexual dysfunction and especially higher sensitivity resulting to orgasmic quality [5]. Patients are advised to resume social activities at once [42].

Liposuction

Enlarged or ptotic labia majora may be present in obese women. In cases where the main source of hypertrophy is adipose tissue, liposuction can be quite helpful. The same application is also used in cases of enlarged mons pubis. Liposuction is performed using 3-mm cannulae [10]. Ultrasound-assisted liposuction is superior to conventional in terms of symmetry and leaves a smoother contour [4,6,10]. There have been cases where this technique was performed aggressively and as result women experienced skin relaxation and irregular contour.

Liposuction of the mons pubis: Useful and common intervention to reduce the size of the mons pubis as hormone and fat levels in the body define its size. Mons's pubis enlargement causes no clear medical pathologies but may lead to embarrassment on several occasions and thus deteriorate body image perception [4,6,10].

Discussion

FGCS involves a wide range of interventions (such as vaginal rejuvenation, G-spot amplification, labiaplasty, revirgination with hymenoplasty, and vulvar liposculpturing) including surgical and non-surgical methods [3,4,9]. Combinations of treatments are increasingly used. Office modalities are gaining popularity and acceptance through the years as they are minimally invasive with increased safety and efficacy and without major complications reported [5] (Table 1). Although, little scientific evidence supports the improvement of sexual satisfaction [5].

Healthy sexuality is complex and combines multiple factors such as cultural, relational, psychological, and anatomical. FGCS seems to reduce sexual discomfort, and increase sexual pleasure of both partners, although data is limited [4,10]. Discussion with the patient, psychological guidance and personal assessment are suggested, so that unrealistic expectations are avoided, and women's concerns, deepest thoughts, and desired outcomes are expressed [10]. Health providers should explain to the patient that these techniques are not directly aimed at improving sexual life [4]. Clinical evaluation may be used to exclude specific mental disorders, like body dysmorphic disorder and depression, as they may influence the final decision of undergoing FGCS [2,3,14]. The age from which a teenager can decide on an intervention herself varies by country. The genital change morphology during lifespan and can lead to an ultimately undesirable outcome with physical and mental effects on the individual [35]. In other words, FGCS interventions are not recommended for women less than 18 years of age [35].

Cosmetic gynaecology has been accused by some as a form of female genital mutilation (FGM) due to modification of normal external genitalia [3,35]. FGM violates human rights and obviously, all forms of FGM are opposed by WHO [43]. WHO defines FGM as "female genital mutilation (FGM) comprises all procedures that involve partial or total removal of the external female genitalia, or other injury to the female genital organs for non-medical reasons", and states that legally accepted procedures are not considered necessarily FGM but may fall under its definition [43,44].

Therefore, defining the boundaries between FGCS and FGM is essential [18].

Women undergoing FGCS are within the normal variability of function and anatomy, however, they have the right to choose according to their desires, although the burden of such interventions relies on health professionals [14]. There is lack of knowledge about what constitutes normal regarding sexual function and anatomy, so preoperative counseling about genital diversity and correction of genital perception may prevent unnecessary procedures [9,11,14]. Cosmetic gynaecology procedures should be tailored by health professionals to achieve and design the most appropriate strategy [10]. Depending on the goals and expectations, the techniques for each woman should be adjusted accordingly [17].

Office procedures are easy, timesaving, efficient, and safe techniques for improvement of sexual dysfunction but they require additional sessions to maintain the clinical outcomes. Treatment protocol is defined based on the chosen method and more evidence is required to determine long-term effects of these modalities, as well as, to decide the frequency of sessions and whether combinations with other similar methods are needed.

Conflict of Interest

All authors declare neither conflict of interest nor funding of any kind.

References

1. Barbara G, Facchin F, Buggio L, Alberico D, Frattaruolo MP, Kustermann A. Vaginal rejuvenation: current perspectives. *Int J Womens Health*. 2017; 9:513-519. Doi: <https://doi.org/10.2147/IJWH.S99700>
2. Barbara G, Facchin F, Meschia M, Vercellini P. "The first cut is the deepest": a psychological, sexological and gynecological perspective on female genital cosmetic surgery. *Acta Obstet Gynecol Scand*. 2015; 94(9):915-920. Doi: <https://doi.org/10.1111/aogs.12660>
3. Halder GE, Iglesia CB, Rogers RG. Controversies in female genital cosmetic surgeries. *Clin Obstet Gynecol*. 2020; 63(2):277-288. Doi: <https://doi.org/10.1097/GRF.0000000000000519>
4. Mullerova J, Weiss P. Plastic surgery in gynaecology: Factors affecting women's decision to undergo labiaplasty. Mind the risk of body dysmorphic disorder: A review. *J Women Aging*. 2018; 00(00):1-18. Doi: <https://doi.org/10.1080/08952841.2018.1529474>
5. Desai SA, Kroumpouzou G, Sadick N. Vaginal rejuvenation: From scalpel to wands. *Int J Women's Dermatology*. 2019; 5(2):79-84. Doi: <https://doi.org/10.1016/j.ijwd.2019.02.003>
6. Wilkie G, Bartz D. Vaginal rejuvenation: a review of female genital cosmetic surgery. *Obstet Gynecol Surv*. 2018; 73(5):287-292. Doi: <https://doi.org/10.1097/OGX.0000000000000559>
7. ICD-10 Version: 2019. <https://icd.who.int/browse10/2019/en#/F52.2>.
8. Latif EZ, Diamond MP. Arriving at the diagnosis of female sexual dysfunction. *Fertil Steril*. 2013; 100(4):898-904. Doi: <https://doi.org/10.1016/j.fertnstert.2013.08.006>
9. Placik OJ, Devgan LL. Female genital and vaginal plastic surgery: An Overview. *Plast Reconstr Surg*. 2019; 144(2):284e-297e. Doi: <https://doi.org/10.1097/PRS.00000000000006660>
10. Triana L, Robledo AM. Aesthetic surgery of female external genitalia. *Aesthetic Surg J*. 2015; 35(2):165-177. Doi: <https://doi.org/10.1093/asj/sju020>
11. Ellibes Kaya A, Dogan O, Yassa M, Basbug A, Ozcan C, Caliskan E. Do external female genital measurements affect genital perception and sexual function and orgasm? *J Turkish Soc Obstet Gynecol*. 2020; 17(3):175-181. Doi: <https://doi.org/10.4274/tjod.galenos.2020.89896>
12. Rowen TS, Gaither TW, Shindel AW, Breyer BN. Characteristics of genital dissatisfaction among a nationally representative sample of U.S. Women. *J Sex Med*. 2018; 15(5):698-704. Doi: <https://doi.org/10.1016/j.jsxm.2018.03.004>
13. Moran C, Lee C. What's normal? Influencing women's perceptions of normal genitalia: an experiment involving exposure to modified and nonmodified images. *BJOG: Int J Obstet Gy*. 2014; 121(6):761-766. Doi: <https://doi.org/10.1111/1471-0528.12578>
14. Cain JM, Iglesia CB, Dickens B, Montgomery O. Body enhancement through female genital cosmetic surgery creates ethical and rights dilemmas. *Int J Gynecol Obstet*. 2013; 122(2):169-172. Doi: <https://doi.org/10.1016/j.ijgo.2013.03.020>
15. Karcher C, Sadick N. Vaginal rejuvenation using energy-based devices. *Int J Women's Dermatology*. 2016; 2(3):85-88. Doi: <https://doi.org/10.1016/j.ijwd.2016.05.003>
16. Vanaman M, Bolton J, Placik O, Fabi SG. Emerging trends in nonsurgical female genital rejuvenation. *Dermatol Surg*. 2016; 42(9):1019-1029. Doi: <https://doi.org/10.1097/DSS.0000000000000697>
17. Gunes A, Alinsod RM. A mini-review of aesthetic

- gynecology and leading gynecology associations' approaches to this issue. *Turk Jinekoloji ve Obstet Dern Derg.* 2018; 15(2):105-111. Doi: <https://doi.org/10.4274/tjod.33407>
18. Garcia B, Scheib S, Hallner B, Thompson N, Schiavo J, Peacock L. Cosmetic gynecology-a systematic review and call for standardized outcome measures. *Int Urogynecol J.* 2020; 31(10):1979-1995. Doi: <https://doi.org/10.1007/s00192-020-04294-5>
 19. Tailor V, Digesu GA, Vieira-Baptista P, Manriquez V, Mourad S. Academic cosmetic gynaecology and energy-based therapies: ambiguities, explorations, and FDA advisories. *Int Urogynecol J.* 2019; 30(6):1021-1022. Doi: <https://doi.org/10.1007/s00192-019-03959-0>
 20. Toplu G, Serin M, Unveren T, Altinel D. Patient reported vaginal laxity, sexual function and stress incontinence improvement following vaginal rejuvenation with fractional carbon dioxide laser. *J Plast Surg Hand Surg.* 2021; 55(1):25-31. Doi: <https://doi.org/10.1080/2000656X.2020.1828897>
 21. Phillips C, Hillard T, Salvatore S, Toozs-Hobson P, Cardozo L. Lasers in gynaecology. *Eur J Obstet Gynecol Reprod Biol.* 2020; 251:146-155. Doi: <https://doi.org/10.1016/j.ejogrb.2020.03.034>
 22. Photiou L, Lin MJ, Dubin DP, Lenskaya V, Khorasani H. Review of non-invasive vulvovaginal rejuvenation. *J Eur Acad Dermatol Venereol.* 2020; 34(4):716-726. Doi: <https://doi.org/10.1111/jdv.16066>
 23. Gold M, Andriessen A, Bader A, Alinsod R, French ES, Guerette N, et al. Review and clinical experience exploring evidence, clinical efficacy, and safety regarding nonsurgical treatment of feminine rejuvenation. *J Cosmet Dermatol.* 2018; 17(3):289-297. Doi: <https://doi.org/10.1111/jocd.12524>
 24. C. A. Fractional CO2 laser treatment for vulvovaginal atrophy symptoms and vaginal rejuvenation in perimenopausal women. *Int J Womens Health.* 2017:591-595. Doi: <https://doi.org/https://www.dovepress.com/fractional-co2-laser-treatment-for-vulvovaginal-atrophy-symptoms-and-v-peer-reviewed-fulltext-article-IJWH>
 25. Tadir Y, Gaspar A, Lev-Sagie A, Alexiades M, Alinsod R, Bader A, et al. Light and energy based therapeutics for genitourinary syndrome of menopause: consensus and controversies. *Lasers Surg Med.* 2017; 49(2):137-159. Doi: <https://doi.org/10.1002/lsm.22637>
 26. Qureshi AA, Tenenbaum MM, Myckatyn TM. Nonsurgical vulvovaginal rejuvenation with radiofrequency and laser devices: a literature review and comprehensive update for aesthetic surgeons. *Aesthetic Surg J.* 2018; 38(3):302-311. Doi: <https://doi.org/10.1093/asj/sjx138>
 27. Ahluwalia J, Avram MM, Ortiz AE. Lasers and energy-based devices marketed for vaginal rejuvenation: A cross-sectional analysis of the MAUDE database. *Lasers Surg Med.* 2019; 51(8):671-677. Doi: <https://doi.org/10.1002/lsm.23084>
 28. Romero-Otero J, Lauterbach R, Aversa A, Serefoglu EC, García-Gómez B, Parnhan A, et al. Radiofrequency-based devices for female genito-urinary indications: position statements from the european society of sexual medicine. *J Sex Med.* 2020; 17(3):393-399. Doi: <https://doi.org/10.1016/j.jsxm.2019.12.015>
 29. Lanzafame RJ, de la Torre S, Leibaschoff GH. The rationale for photobiomodulation therapy of vaginal tissue for treatment of genitourinary syndrome of menopause: an analysis of its mechanism of action, and current clinical outcomes. *Photobiomodulation, Photomedicine, Laser Surg.* 2019; 37(7):395-407. Doi: <https://doi.org/10.1089/photob.2019.4618>
 30. Jabbour S, Kechichian E, Hersant B, Levan P, El Hachem L, Nasr M. Labia majora augmentation: a systematic review of the literature. *Aesthetic Surg J.* 2017; 37(10):1157-1164. Doi: <https://doi.org/10.1093/asj/sjx056>
 31. Menkes S, SidAhmed-Mezi M, Meningaud JP, Benadiba L, Magalon G, Hersant B. Microfat and nanofat grafting in genital rejuvenation. *Aesthetic Surg J.* 2020; 41(9):1060-1067. Doi: <https://doi.org/10.1093/asj/sjaa118>
 32. Kim SH, Park ES, Kim TH. Rejuvenation using platelet-rich plasma and lipofilling for vaginal atrophy and lichen sclerosus. *J Menopausal Med.* 2017; 23(1):63. Doi: <https://doi.org/10.6118/jmm.2017.23.1.63>
 33. Puppo V, Gruenwald I. Does the G-spot exist? A review of the current literature. *Int Urogynecol J.* 2012; 23(12):1665-1669. Doi: <https://doi.org/10.1007/s00192-012-1831-y>
 34. Bachelet JT, Mojallal A, Boucher F. Female genital surgery, G-spot amplification techniques-State of the science. *Ann Chir Plast Esthet.* 2014; 59(5):344-347. Doi: <https://doi.org/10.1016/j.anplas.2014.05.003>
 35. Vieira-Baptista P, Almeida G, Bogliatto F, Bohl TG, Burger M, Cohen-Sacher B. International society for the study of vulvovaginal disease recommendations regarding female cosmetic genital surgery. *J Low Genit Tract Dis.* 2018; 22(4):415-434. Doi: <https://doi.org/10.1097/LGT.0000000000000412>
 36. Park HJ, Jung KH, Kim SY, Lee JH, Jeong JY, Kim JH. Hyaluronic acid pulmonary embolism: a critical consequence of an illegal cosmetic vaginal procedure. *Thorax.* 2010; 65(4):360-361. Doi: <https://doi.org/10.1136/thx.2009.129111>

org/10.1136/thx.2009.128272

37. Yang Y, Sheng H, Gu Q, Su L, Tong H, Qi X. Death caused by vaginal injection of hyaluronic acid and collagen: a case report. *Aesthetic Surg J*. 2020; 40(5):NP263-NP268. Doi: <https://doi.org/10.1093/asj/sjz275>
38. Dawood AS, Salem HA. Current clinical applications of platelet-rich plasma in various gynecological disorders: An appraisal of theory and practice. *Clin Exp Reprod Med*. 2018; 45(2):67-74. Doi: <https://doi.org/10.5653/cerm.2018.45.2.67>
39. Chrysanthopoulou EL, Pergialiotis V, Perrea D, Kourkoulis S, Verikokos C, Doumouchtsis SK. Platelet rich plasma as a minimally invasive approach to uterine prolapse. *Med Hypotheses*. 2017; 104:97-100. Doi: <https://doi.org/10.1016/j.mehy.2017.05.018>
40. Behnia-Willison F, Pour NR, Mohamadi B, Willison N, Rock M, Holten IW, et al. Use of platelet-rich plasma for vulvovaginal autoimmune conditions like lichen sclerosis: *Plast Reconstr Surg - Glob Open*. 2016; 4(11):1-4. Doi: <https://doi.org/10.1097/GOX.0000000000001124>
41. Sukgen G, Elli Bes Kaya A, Karagun E, Caliskan E. Platelet-rich plasma administration to the lower anterior vaginal wall to improve female sexuality satisfaction. *J Turkish Soc Obstet Gynecol*. 2019. Doi: <https://doi.org/10.4274/tjod.galenos.23356>
42. Aguilar P, Hersant B, SidAhmed-Mezi M, Bosc R, Vidal L, Meningaud JP. Novel technique of vulvo-vaginal rejuvenation by lipofilling and injection of combined platelet-rich-plasma and hyaluronic acid: a case-report. *SpringerPlus*. 2016; 5(1):1184. Doi: <https://doi.org/10.1186/s40064-016-2840-y>
43. Park TH, Whang KW. Vaginal rejuvenation with Gore-mycromesh. *Aesth Plast Surg*. 2015; 39(4):491-494. Doi: <https://doi.org/10.1007/s00266-015-0502-z>
44. Female genital mutilation. <https://www.who.int/news-room/fact-sheets/detail/female-genital-mutilation>.



Copyright: © **Anagnostou et al.** This is an Open Access article distributed under the terms of the Creative Commons Attribution License, which permits unrestricted use, distribution, and reproduction in any medium, provided the original work is properly cited.