

Research Article

Current Opinion in Gynecology and Obstetrics

Spectral Artificial Vision Endoscopy for Assisting the Differential Diagnosis of Endometrial Polyps, In Vivo

Gkrozou F^{1*}, Rossos C^{2,3}, Tsapras A^{2,3}, Kortsalioudakis N^{2,3}, Tsonis O⁴, Balas C^{2,3} and Paschopoulos M⁴

¹University Hospitals of Birmingham, NHS Foundation Trust, England

²School of Electrical and Computer Engineering, Technical University of Crete, Chania, Greece

³QCELL PC, Chania, Greece

⁴University of Ioannina, Department of Obstetrics and Gynaecology, Greece

***Correspondence:** Fani Gkrozou, University Hospitals of Birmingham, NHS Foundation Trust, England, E-mail: fani.gkrozou@gmail.com

Received date: March 10, 2021; Accepted date: May 19, 2021; Published date: May 25, 2021

Abstract

We are the first to present results from a pilot clinical study designed for the purpose of establishing spectral mapping patterns, as a potential novel imaging assay for identifying and discriminating between functional and nonfunctional endometrial polyps *in vivo*. The Spectral Artificial Vision Endoscope (SAVE) was used and validated in this study. The SAVE system, adapted to a regular hysteroscope, was able to operate in several imaging modes, including color imaging, infrared imaging, narrow band imaging and spectral mapping, all acquired at a video rate and simultaneously. The spectral maps generated by the SAVE system for 28 patients with endometrial polyps displayed characteristic patterns capable of discriminating functional from nonfunctional polyps with remarkable consistency (Spearman R=0.912, p<10⁻⁶). These preliminary clinical validation results highlighted the great potential of the *in vivo* spectral mapping imaging modality as an adjunct tool to conventional color camera-based hysteroscopy, offering improved and quantitative diagnosis.

Keywords: Spectral imaging, artificial vision, endoscopy, hysteroscopy, polyps

Introduction

Transvaginal Ultrasound (TVS) is a first-line diagnostic option in cases of Intermenstrual Bleeding (IMB), menorrhagia, Abnormal Uterine Bleeding (AUB) or Post-Menopausal Bleeding (PMB), that facilitates prompt detection and possible identification of any underlying endometrial pathology [1,2]. The sonographic investigation is often followed by hysteroscopy, which allows direct visualization of the endometrial cavity and permits guided-biopsy sampling from suspicious areas, when needed. Histology of the tissues, obtained by biopsies, remains the gold standard, providing the definitive diagnosis [3]. Endometrial polyps (EPs) are responsible for approximately

25% of the AUB cases in both pre- and post-menopausal women [1], while IMB is by far the most common symptom associated with their presence. Notably, small and asymptomatic EPs are often incidentally found via TVS. In general, EPs are localized hyperplastic overgrowths of endometrial glands and stroma around a vascular core. They appear either as a sessile or as a pedunculated projection arising from the endometrial surface, with the pedunculated polyps being more common than the sessile ones [1,2]. Pedunculated EPs are attached on a thin stalk, while the sessile type is connected with a flat base to the underline endometrial mucosa and the

myometrium. Single or multiple polyps can be found, ranging in size from few millimeters to several centimeters [4-8]. Histopathologic examination usually reveals that they consist of dense, fibrous tissues (stroma), with blood vessels and glandular-like spaces lined with endometrial epithelium. EPs resting in the functional layer are hormonally responsive and are classified as functional polyps. Functional EPs and endometritis are common findings in women with implantation failure and recurrent miscarriages [9]. Moreover, there are several clinical studies suggesting the inclusion of functional EPs on the spectrum of the inflammatory endometrial diseases [9-13]. Additionally, there is also another broad EP category known as “non-functional” EPs that includes carcinomatous, atrophic, or hyperplastic [14] types. This EP category is typically persisting and may eventually progress towards a malignant transformation or reduce endometrial receptivity [15].

Although EPs are very common, their etiopathogenesis is still not fully understood and described, while their management remains largely non standardized. Routine clinical examination takes into account EPs size and patient’s age in order to decide on either conservative or surgical management approach. Small sizes EPs (<10mm) are expected to regress spontaneously, especially in younger asymptomatic women. On the contrary, persisting EPs in postmenopausal women present a 10-fold higher risk for malignancy, when compared with women of reproductive age [15,16], suggesting the necessity of further surgical removal. Besides size and patient’s age, the location of EPs seems to be essential, with evidence supporting that EPs closer to the tubal origin are more likely to manifest malignant potential. The exact mechanism correlating EPs and fertility issues remains still unknown. Lőrincz et al. [17], has shown that polypectomy improved the conception rate in the subsequent years regardless of the intrauterine localization and the exact method of its surgical removal. There is therefore clinical evidence suggesting that polypectomy should be considered in infertile women. The same study suggests that when histology confirms normal or functional EPs, there is no evidence supporting that their presence has an impact on fertility [17].

Hysteroscopic evaluation and resection is the most effective management for EPs, since it further allows histologic assessment of the specimens. However, the identification and the discrimination between the different EPs types remain today a challenging clinical task, with great impact on treatment decision-making. Functional polyps, for example, usually disappear within a 2 to 3 month’s period, most likely due to endometrial shedding

during menstruation [18,19]. If not identified correctly, their removal will not alleviate patient’s symptoms; while at the same time will increase the risks associated with a possible surgical overtreatment. On the other hand, accurate identification of non-functional polyps will promote their surgical removal, thus minimizing patient’s morbidity [20,21].

The need for advancing hysteroscopic technology for investigating the etiopathogenesis of EPs in conjunction with the demand for developing novel, objective diagnostic approaches for *in vivo* identification and classification of EPs, has motivated our work presented in this paper. More specifically, we utilize a novel spectral imager adapted to a regular hysteroscope to study various EPs types seeking for their spectral “signatures”, in an attempt to develop an *in vivo* assay for their objective and unambiguous identification. We present and discuss results from a small pilot study conducted with the purpose of acquiring and analyzing the spectral mapping patterns of functional and nonfunctional polyps with the goal of establishing additional, spectroscopy-based clinical criteria with the potential to assist clinical management decision-making.

Materials and Methods

Spectral artificial vision endoscope (SAVE)

Even though endoscopic technology has developed over the years, there are still significant limitations, particularly with regards to the diagnostic capabilities of conventional color camera-based endoscopes. Modern endoscopes with digital color cameras are based on the three primary color detection principle, emulating human vision. Color imaging/vision compromises spectral information for the benefit of scene perception speed and image definition. Human vision and color cameras are both sensitive in a narrow band of electromagnetic spectrum, which restricts the diagnostic content of the acquired digital images. Very often, different tissue lesions display similar hues or remain undetectable due to their poor contrast with the surrounding tissue. Moreover, in several cases it is difficult to identify the severity of lesions and to judge their extent because subtle pathologic alterations often merge with the surrounding normal tissue. There is therefore a clear and unmet need for advanced imaging technology of endoscopy in general, in an attempt to improve the diagnostic outcomes. Recent technological developments offer a great potential for removing the trade-offs between speed, spatial and spectral information, towards maximizing the diagnostic information that can be gained. Video-rate multichannel imaging systems with sensitivity in both the visible and the non-visible spectral ranges emerge as

the successors of conventional color cameras as well as, of hyper-/multi-spectral cameras, requiring prolonged scanning times. Near infrared multichannel imaging allows for the visualization of subsurface features of diagnostic importance. Moreover, multichannel imaging generates not just three primary colors per pixel but a full rainbow of colors, making up a full spectrum per pixel. This is valuable because spectra are informative about the biochemical and structural alterations that are often accompanying the progress of a disease. Capitalizing on previous work by our group [20-22] and by other researchers [23,24] in the fields of hyperspectral imaging and Narrow-Band imaging, co-author CB at QCELL has invented the SAVE imaging system [25] figure 1 comprising: a) a dual sensor camera coupled with specially designed optics that make possible the video rate, simultaneous acquisition of six (6) narrow band images (35 with spectral estimation) and one color image, with a spatial resolution of six (6) megapixels each; b) a multichannel LED, heating-free light source with continuous spectral emission, spanning the spectral range 400-1000nm; c) a bifurcated fiber optic bundle transferring and multiplexing LED light to the endoscope; d) an i9 level computer system executing the system's software and displaying the images on the dual monitor arrangement; e) specially developed software, offering camera and light source control through a graphical user interface, selection/activation of imaging modes and processing/analysis of imaging data. The SAVE hysteroscope (SAVE-H) operates in a variety of imaging modes including: reflection, fluorescence (with excitation at 410 nm), near infrared (two bands), narrow band imaging in five bands, spectroscopy and spectral mapping modes. All imaging modes are real-time displayed side-by-side with a high definition color image for reference (Figure 1). The software module of SAVE-H performs several advanced operations, such as spectral estimation, spectral classification and mapping without user intervention. The SAVE-H system is regularly calibrated to reference samples with known spectral characteristics, for compensating possible electronic drifts due to temperature variations and equipment aging and for ensuring device-independent color and spectral imaging. Spectral classification and mapping generate a real time displayed pseudocolor image, with each color-coding representing a distinguishable spectral class within the field of view. The working hypothesis of this study was that the spectra acquired per image pixel and the corresponding spectral mapping will depict consistently invisible anatomical microstructural variations with high accuracy offering sufficient confidence to use the spectral mapping images as useful assay for differentiating different categories of Eps.

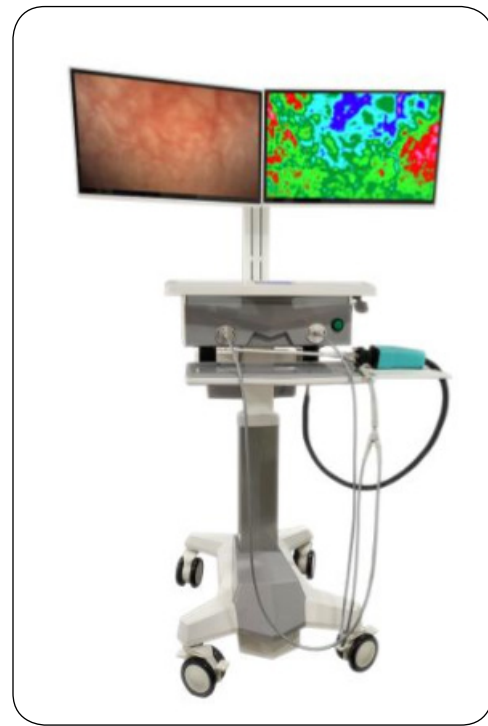


Figure 1: The spectral artificial vision endoscope.

Pilot study design

The SAVE-H system was used in a small pilot study designed for the purpose of verifying whether different types of EPs display different spectral mapping profiles. Emphasis was given to the discrimination between functional and non-functional EPs. The SAVE-H system was operated solely by the gynecologists participating in this study, since there is no need for a specialized technical background, in order to perform the examination. Thirty-six women referred to the Endoscopic Unit of the Department of Obstetrics and Gynaecology at the University Hospital of Ioannina, Greece, with the indication of AUB and PMB. All patients signed off an informed consent. The study protocol was approved by the Institutional Review Board of the Hospital.

All patients received the clinic's standard diagnostic protocol which is appropriate for women with AUB and PMB. According to this protocol, the diagnostic approach consists of an initial TVS evaluation followed by diagnostic hysteroscopy. Women were referred for SAVE hysteroscopy (SAVE-H) when TVS was suggestive of the presence of EPs and/or when hyperechoic areas were detected within the two endometrial layers or in the presence increased endometrial thickness. Office SAVE-H was performed exactly as the traditional office hysteroscopy with vaginoscopic approach and the use of normal saline as distention medium. The SAVE-H camera was adapted to a semi-rigid Karl Storz hysteroscope with a 5mm diagnostic sheath.

Premenopausal women had hysteroscopy between the 11th and 13th day of menstrual cycle as per optimal endometrial visualization [6]. The endometrial cavity was fully explored searching for the TVS-indicated EPs, with the monitors displaying in real time both color and spectral mapping image. When EPs were detected on the basis of their routine clinical evaluation criteria, a series of images corresponding to all imaging modes were captured simultaneously with a single snapshot, in order to eliminate motion artifacts and to ensure their accurate alignment with respect to each other. Multichannel image registration is essential for calculating the spectral maps, since spectral analysis requires accurate, pixel-level spectral image co-registration. After establishing the presence of a polyp, patients were offered an operative hysteroscopy to obtain a final histological diagnosis. Patients with other abnormal hysteroscopic findings were also offered an operative hysteroscopy but they were excluded from the study. Patients with normal endometrial appearance were excluded too.

Results

All women completed SAVE-H successfully. In 5 women with AUB, no endometrial pathology was recognized after TVS and SAVE-H examination and were excluded from the study. Three more patients were excluded, one with sub mucosal fibroid (n=1) and two with endometrial hyperplasia (n=2), since, according to the study protocol, eligible cases where only considered patients with EPs. Mean age was 54±3.60 years (range from 42 -75 years). Eight women were postmenopausal and 20 were pre-menopausal. Patients enrolled had no chronic disease to report and no hormonal regime had been previously administered.

SAVE-H displayed at video rates color, spectral and spectral map images. These images were captured simultaneously and spectral map patterns were correlated with histology. SAVE-H identified 20 nonfunctional EPs and 8 functional EPs on the basis of their spectral mapping patterns. Figure 2 illustrates the color image of one functional EP (a); the spectral map (b); the 550nm spectral image (c); and the 850 nm spectral image of the same EP. Figure 2 illustrates the same color/spectral images but for a nonfunctional EP. As discussed earlier, a certain artificial color is assigned automatically to tissue areas with similar spectral profiles. Different artificial colors in a spectral map image represent pixel areas with different spectral profiles which, in turn, may represent microstructural and functional variations associated with a tissue condition. SAVE-H software integrates efficient spectral classifiers that group the intensity normalized spectra, which are

not sensitive to random light intensity changes due to the uncontrollable variations of tissue-endoscope distance. Figure 3, it was observed that the spectral mapping images figure 2b and figure 3b correspond to functional and to nonfunctional EPs display different spectral mapping patterns with a remarkable consistency. Particularly, the purple class is found in large areas in the functional EPs maps, while the red class dominates in the nonfunctional EPs spectral maps. The green and blue areas correspond to normal tissue areas in both cases. As it is evidenced in figure 2c and 2d and figure 3c and 3d, the darker image shades of the 550 nm 2c image in relation to its 850nm 2d counterpart indicate stronger absorption in this band than the corresponding of the non-functional EPs. This is possibly a sign for the presence of inflammation in this EPs category, which is in agreement with findings from other clinical studies [9,10]. Histology revealed just one inconsistency with this general trend. In one EP displaying a functional spectral map profile, a nonfunctional EP histology report was received. Despite this single case discordance, the correlation between SAVE-H spectral mapping patterns and histology assessments of the same functional and nonfunctional EPs was found to be closely correlated (Spearman R=0.912) with $p < 10^{-6}$ significance. The sensitivity of this method in discriminating nonfunctional from functional EPs was found to be 95% and the specificity 100%. The Positive and Negative Predictive Values were found to be PPV=100% and the NPV=88% respectively.

Discussion and Conclusions

Color imaging hysteroscopy in conjunction with a focal biopsy or curettage is considered the golden standard achieving definitive diagnosis. However, clinical trials have shown a widely varying diagnostic performance [26]. The reported diagnostic performance of the established diagnostic chain, including color camera hysteroscopy, are far from satisfactory to confront with the increased incidence of life-threatening pathologies of the endometrium. There is therefore an unmet need for advancing diagnostic technologies since the death rate of endometrial cancer has increased more than 100% during the past 20 years in the US, rising by 8% since 2008 [27]. Hyper- or multi-spectral imagers can measure the spectral content of light energy at every point in an image. As such, they comprise a unique tool for seeking spectral signatures of tissue lesions, depicting their altered structure and function. It should be noted however that implementing spectral imaging technology into clinical endoscopy is not a trivial task. Conventional spectral imagers require prolonged scanning times to collect images across the spectrum. During this

scanning process, the endoscope's tip should be held still (at the submicron level) in relation to the target tissue, something that is often difficult to achieve in endoscopic practices. Another reason that makes conventional spectral imagers impractical for endoscopy is that they require long, post capturing image processing, not allowing real-time spectral mapping-based inspections, which is a key requirement in routine examinations.

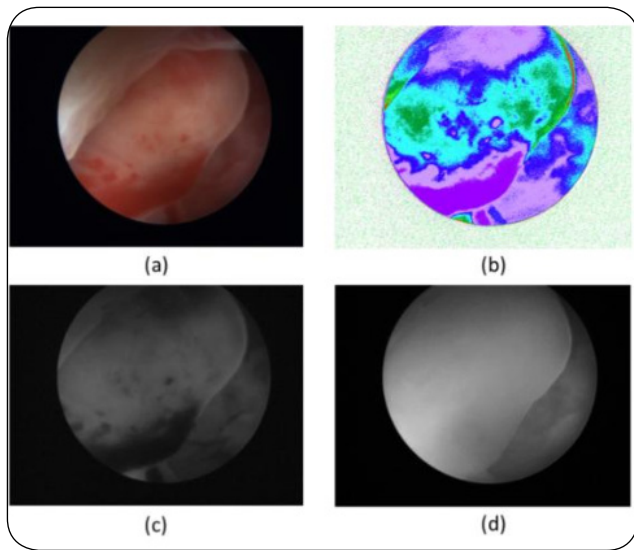


Figure 2: The color image of a functional endometrial polyp (a); the spectral map (b); the 550nm spectral image (c); and the 850nm spectral image of the same polyp.

In this study, spectral mapping patterns of EPs are presented for the first time. The study has also demonstrated that video rate spectral imaging and mapping have removed the scanning-processing time-related barriers, prohibiting the implementation of spectral imaging in endoscopy/hysteroscopy. Within the context of this pilot clinical study, the working hypothesis and expected outcomes were confirmed and summarized as to whether the histological differences observed between functional and nonfunctional EPs are reflected with adequate consistency. It should be noted however that this is a single center, small size study defines the preliminary nature of our findings. Thus the findings of this study are utilized as a calibration data set for the SAVE-H system. We are currently in the process of designing a multicenter, two arm validation clinical trial for the purpose of establishing trustable sensitivity-specificity figures. In parallel, our team is currently conducting research towards establishing spectral mapping patterns for a long list of endometrial abnormalities, including the ones frequently found commonly in infertile women. Interestingly, EPs are common hysteroscopic findings in more than 25% of women suffering from infertility, even

though the majority of them remains asymptomatic [28].

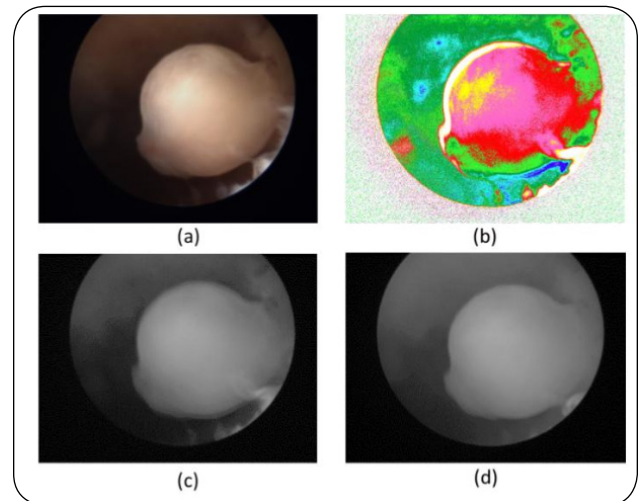


Figure 3: The color image of a non functional endometrial polyp (a); the spectral map (b); the 550nm spectral map (c); and the 850nm spectral image of the same polyp.

Spectral vision hysteroscopy emerges as a novel and promising endoscopic modality, with great short-term potential to establish spectral mapping as an adjunct tool to conventional color camera-based hysteroscopy. The main benefit of SAVE-H system is the integration of both high-definition digital color and spectral mapping imaging modalities in a single workstation allowing direct comparative evaluation of their corresponding imaging patterns. As for now, SAVE-H offers several new dimensions of information, useful in hysteroscopy for both routine and research purposes.

Conflict of interest

All authors declare no conflict of interest.

References

1. McFarlin BL. Ultrasound assessment of the endometrium for irregular vaginal bleeding. *J Midwifery Womens Health*. 2006; 51(6):440-449. Doi: <https://doi.org/10.1016/j.jmwh.2006.06.002>
2. Miseljic N, Izetbegovic S, Mehmedbasic S, Miseljic S. Congenital anomalies of the uterus, and ultrasound diagnostics. *Med Arh*. 2010; 64(2):119-120. <https://pubmed.ncbi.nlm.nih.gov/20514782/>
3. Reznak L, Kudela M. Comparison of ultrasound with hysteroscopic and histological findings for intrauterine assessment. *Biomed Pap Med Fac Univ Palacky Olomouc Czech Repub*. 2018; 162(3):239-242. Doi: <https://doi.org/10.5507/bp.2018.010>

4. Iyer RB, Balachandran A. PET/CT and cross sectional imaging of gynecologic malignancy. *Cancer Imaging*. 2007; 7(Special Issue A):S130-S138. Doi: <https://doi.org/10.1102/1470-7330.2007.9015>
5. Wang JH, Zhao J, Lin J. Opportunities and risk factors for premalignant and malignant transformation of endometrial polyps: management strategies. *J Minim Invasive Gynecol*. 2010; 17(1):53-58. Doi: <https://doi.org/10.1016/j.jmig.2009.10.012>
6. Cicinelli E, Pinto V, Tinelli R, Saliani N, De Leo V, Cianci A. Rapid endometrial preparation for hysteroscopic surgery with oral desogestrel plus vaginal raloxifene: a prospective, randomized pilot study. *Fertil Steril*. 2007; 88(3):698-701. Doi: <https://doi.org/10.1016/j.fertnstert.2006.11.151>
7. Gerber B, Krause A, Reimer T, et al. Anastrozole versus tamoxifen treatment in postmenopausal women with endocrine-responsive breast cancer and tamoxifen-induced endometrial pathology. *Clin Cancer Res*. 2006; 12(4):1245-1250. Doi: <https://doi.org/10.1158/1078-0432.CCR-05-0225>
8. de Carvalho S, Campaner AB, Lima SMRR, Silva MALG, Ribeiro PAA. Differential expression of estrogen and progesterone receptors in endometrial polyps and adjacent endometrium in postmenopausal women. *Anal Quant Cytol Histol*. 2011; 33(2):61-67. <https://pubmed.ncbi.nlm.nih.gov/21980607/>
9. Carvalho FM, Aguiar FN, Tomioka R, de Oliveira RM, Frantz N, Ueno J. Functional endometrial polyps in infertile asymptomatic patients: a possible evolution of vascular changes secondary to endometritis. *J Eur J Obstet Gynecol Reprod Biol*. 2013; 170(1):152-156. Doi: <https://doi.org/10.1016/j.ejogrb.2013.05.012>
10. Stamatellos I, Apostolides A, Stamatopoulos P, Bontis J. Pregnancy rates after hysteroscopic polypectomy depending on the size or number of the polyps. *Arch Gynecol Obstet*. 2008; 277(5):395-399. Doi: <https://doi.org/10.1007/s00404-007-0460-z>
11. Cicinelli E, Resta L, Nicoletti R, Zappimbulso V, Tartagni M, Saliani N. Endometrial micropolyps at fluid hysteroscopy suggest the existence of chronic endometritis. *Hum Reprod*. 2005; 20(5):1386-1389. Doi: <https://doi.org/10.1093/humrep/deh779>
12. Cicinelli E, Tinelli R, Lepera A, Pinto V, Fucci M, Resta L. Correspondence between hysteroscopic and histologic findings in women with chronic endometritis. *Acta Obstet Gynecol Scand*. 2010; 89(8):1061-1065. Doi: <https://doi.org/10.3109/00016349.2010.498496>
13. Mollo A, Stile A, Alviggi C, et al. Endometrial polyps in infertile patients: do high concentrations of interferon-gamma play a role? *Fertil Steril*. 2011; 96(5):1209-1212. Doi: <https://doi.org/10.1016/j.fertnstert.2011.08.001>
14. Tanos V, Berry KE, Seikkula J, et al. The management of polyps in female reproductive organs. *Int J Surg*. 2017; 43:7-16. Doi: <https://doi.org/10.1016/j.ijisu.2017.05.012>
15. Tanos V, Toney A, RAAD E, Berry K, Sleiman Z. Management of endometrial polyps. *Journal of Women Health Care And Issues*. 2019;2(1).
16. Di Spiezio Sardo A, Di Carlo C, Minozzi S, et al. Efficacy of hysteroscopy in improving reproductive outcomes of infertile couples: a systematic review and meta-analysis. *Hum Reprod Update*. 2016; 22(4):479-496. Doi: <https://doi.org/10.1093/humupd/dmw008>
17. Lőrincz J, Molnár S, Jakab A, Herman T, Jashanjeet S, Török P. The effect of localization and histological verification of endometrial polyps on infertility. *Arch Gynecol Obstet*. 2019; 300(1):217-221. Doi: <https://doi.org/10.1007/s00404-019-05155-3>
18. DeWaay D. Natural history of uterine polyps and leiomyomata. *Obstet Gynecol*. 2002; 100(1):3-7. Doi: [https://doi.org/10.1016/S0029-7844\(02\)02007-0](https://doi.org/10.1016/S0029-7844(02)02007-0)
19. Yuksel S, Tuna G, Celik HG, Salman S. Endometrial polyps: Is the prediction of spontaneous regression possible? *Obstet Gynecol Sci*. 2021; 64(1):114-121. Doi: <https://doi.org/10.5468/ogs.20242>
20. Kavvadias V, Epitropou G, Georgiou N, Grozou F, Paschopoulos M, Balas C. A novel endoscopic spectral imaging platform integrating k-means clustering for early and non-invasive diagnosis of endometrial pathology. In: *35th Annual International Conference of the IEEE Engineering in Medicine and Biology Society (EMBC)*. Osaka: IEEE; 2013:3-7. Doi: <https://doi.org/10.1109/EMBC.2013.6610532>
21. Balas C, Papoutsoglou G, Potirakis A. *in vivo* molecular imaging of cervical neoplasia using acetic acid as biomarker. *IEEE J Select Topics Quantum Electron*. 2008; 14(1):29-42. Doi: <https://doi.org/10.1109/JSTQE.2007.913396>
22. Soutter WP, Diakomanolis E, Lyons D, et al. Dynamic spectral imaging: improving colposcopy. *Clin Cancer Res*. 2009; 15(5):1814-1820. Doi: <https://doi.org/10.1158/1078-0432.CCR-08-1636>
23. uznetsov K, Lambert R, Rey JF. Narrow-band imaging: potential and limitations. *Endoscopy*. 2006; 38(01):76-81. Doi: <https://doi.org/10.1055/s-2005-921114>
24. Gono I. Multifunctional Endoscopic Imaging System for Support of Early Cancer Diagnosis. *IEEE Journal of*

Selected Topics in Quantum Electronics. 2008; 8(14):62-69,200.

25. Balas K. A hybrid spectral imager. No 10,989,595 United States Patent and Trademark Office. <https://patentscope.wipo.int/search/en/detail.jsf?docId=WO2020025987>
26. Garuti G, Cellani F, Garzia D, Colonnelli M, Luerti M. Accuracy of hysteroscopic diagnosis of endometrial hyperplasia: A retrospective study of 323 patients. *J Minim Invasive Gynecol.* 2005;12 (3):247-253. Doi: <https://doi.org/10.1016/j.jmig.2005.03.006>
27. Braun MM, Overbeek-Wager EA, Grumbo RJ. Diagnosis and management of endometrial cancer. *Am Fam Physician.* 2016; 93(6):468-474. <https://pubmed.ncbi.nlm.nih.gov/26977831/>
28. Munro MG. Uterine polyps, adenomyosis, leiomyomas, and endometrial receptivity. *Fertil Steril.* 2019; 111(4):629-640. Doi: <https://doi.org/10.1016/j.fertnstert.2019.02.008>



Copyright: © **Gkrozou et al.** This is an Open Access article distributed under the terms of the Creative Commons Attribution License, which permits unrestricted use, distribution, and reproduction in any medium, provided the original work is properly cited.